

An algorithm for the preoperative diagnosis and treatment of ocular surface disorders



Christopher E. Starr, MD, Preeya K. Gupta, MD, Marjan Farid, MD, Kenneth A. Beckman, MD, Clara C. Chan, MD, FRCSC, Elizabeth Yeu, MD, José A.P. Gomes, MD, PhD, Brandon D. Ayers, MD, John P. Berdahl, MD, Edward J. Holland, MD, Terry Kim, MD, Francis S. Mah, MD, the ASCRS Cornea Clinical Committee

Any ocular surface disease (OSD), but most commonly, dry-eye disease (DED), can reduce visual quality and quantity and adversely affect refractive measurements before keratorefractive and phacorefractive surgeries. In addition, ocular surgery can exacerbate or induce OSD, leading to worsened vision, increased symptoms, and overall dissatisfaction postoperatively. Although most respondents of the recent annual American Society of Cataract and Refractive Surgery (ASCRS) Clinical Survey recognized the importance of DED on surgical outcomes, many were unaware of the current guidelines and most were

not using modern diagnostic tests and advanced treatments. To address these educational gaps, the ASCRS Cornea Clinical Committee developed a new consensus-based practical diagnostic OSD algorithm to aid surgeons in efficiently diagnosing and treating visually significant OSD before any form of refractive surgery is performed. By treating OSD preoperatively, postoperative visual outcomes and patient satisfaction can be significantly improved.

J Cataract Refract Surg 2019; 45:669-684 © 2019 ASCRS and ESCRS

Dry-eye disease (DED) is a common cause of patients seeking medical advice and a frequent source of blurry or fluctuating vision.¹ We know that patients who have DED and are considering keratorefractive surgery, in particular, laser in situ keratomileusis (LASIK), should be cautioned that these surgeries might worsen their DED or other ocular surface conditions.² DED should be treated effectively before the patient has keratorefractive or phacorefractive surgery.³ DED can cause a reduced visual function and might compromise the overall results of corneal, cataract, and refractive surgery.^{4,5} The incidence of DED and ocular surface disease (OSD) in cataract surgery candidates who are asymptomatic is higher than previously thought. In one study,⁶ upwards

of 60% of routine cataract patients were asymptomatic, yet 50% had central corneal staining. In another study,⁷ the incidence of OSD in patients presenting for cataract surgery was over 80%, and in those who were asymptomatic, over 50% had an abnormal tear osmolarity or matrix metalloproteinase-9 (MMP-9) level. The impact of DED and OSD on topography, biometry, keratometry, and higher-order aberrations is one of the major causes of disappointing postoperative outcomes.^{8,9}

The annual American Society of Cataract and Refractive Surgery (ASCRS) Clinical Survey of its membership identified DED and OSD as recurring general sources of confusion. In the past few years, more than 75% of respondents were unfamiliar with the TFOS DEWS II (Tear Film &

Submitted: August 25, 2018 | Final revision submitted: December 18, 2018 | Accepted: December 19, 2018

From Weill Cornell Medicine, New York-Presbyterian Hospital (Starr), New York, New York, Duke University Eye Center, (Gupta, Kim), Durham, North Carolina, Gavin Herbert Eye Institute (Farid), University of California, Irvine, the Department of Ophthalmology, The Ohio State University and Comprehensive EyeCare of Central Ohio (Beckman), Westerville, Ohio, Eastern Virginia Medical School, Virginia Eye Consultants (Yeu), Norfolk, Virginia, Vance Thompson Vision (Berdahl), Sioux Falls, South Dakota, Wills Eye Hospital (Ayers), Philadelphia, Pennsylvania, Cincinnati Eye Institute (Holland), University of Cincinnati, Ohio, Scripps Clinic (Mah), La Jolla, California, USA; the Department of Ophthalmology and Vision Sciences, University of Toronto (Chan), Ontario, Canada; Paulista Medical School (Gomes), Federal University of São Paulo, Brazil.

Supported by the ASCRS and a departmental unrestricted grant from Research to Prevent Blindness (C.E.S., Weill Cornell Medicine). The funding organizations had no role in the design or conduct of this research.

We would like to thank Johnson & Johnson for allowing the use and modification of the SPEED questionnaire and Steven Dell, MD, for the use and modification of his Cataract & Refractive Lens Exchange Questionnaire.

Corresponding author: Christopher E. Starr, MD, Weill Cornell Medicine, New York-Presbyterian Hospital, Department of Ophthalmology, 1305 York Ave, New York, NY 10021, USA. Email: cestarr@med.cornell.edu.

Ocular Surface Society Dry Eye WorkShop II)¹⁰ and the Delphi Panel International Task Force recommendations.¹¹ Although only 9% were using osmolarity and 5% were using MMP-9 testing, 91% felt that mild-to-moderate DED impacts patient satisfaction in cataract and refractive surgery. In 2017, 83% of respondents indicated they would find an algorithm for ocular surface diagnostics valuable, especially in relation to refractive surgical patients. These perceived gaps in clinical practice, lack of awareness of the most current OSD tools and guidelines, and the additional complexities of managing OSD in surgical populations motivated the ASCRS Cornea Clinical Committee to undertake this novel educational effort.

There has been a rapid rise in commercially available point-of-care diagnostic tests; however, their adoption, especially with presurgical patients, has been slow. The following ASCRS Cornea Clinical Committee recommendations were created with the intent to reduce surgeon chair time via greater reliance on physician extenders, technicians, and these novel point-of-care objective tests while increasing the preoperative diagnosis of potentially visually significant OSD (VS-OSD). Although some of our recommendations might suggest nonreimbursed tests (eg, osmolarity in an asymptomatic patient), our thought is that the small cost of performing these potentially nonreimbursable point-of-care tests can be bundled into a premium intraocular lens (IOL) and/or keratorefractive surgery package.

DED advancement has historically been limited by a lack of uniformity in its definition and the inability of any single diagnostic test or set of diagnostic tests to confirm or rule out the condition. Publications such as the Cornea, External Disease and Refractive Society's dysfunctional tear syndrome (DTS),¹² TFOS DEWS II,¹⁰ and the Delphi Panel DTS¹¹ brought together multiple experts to create consensus documents on recommended practices to help advance and unify the field of DED. The recommendations of our committee are in no way a difference of opinion, or competitive in nature; in fact, many of our recommendations are synthesized and adapted from the knowledge gained from these seminal publications. Unlike previous protocols and algorithms, ours is intended specifically for the perioperative refractive surgery patient. Our algorithm is based on the ASCRS Cornea Clinical Committee members' collective consensus on preferred practices. We are not suggesting that these recommendations are the new standard of care or should be rigidly adhered to in every practice. Although easily adoptable by most, our novel algorithm and questionnaire can also be easily modified and personalized to suit any practice workflow.

As a uniquely challenging yet highly critical patient encounter in the modern era, the preoperative office visit is demanding of patients, physicians, and office staff alike. As busy cataract and refractive surgeons, the ASCRS Cornea Clinical Committee members understand the increasing daily demands of a surgical ophthalmic practice and the time and energy involved for each preoperative patient visit (eg, obtaining consent, counseling, scheduling, billing, paperwork, diagnostic testing, multiple IOL and refractive

options, out-of-pocket costs, etc.). Although addressing OSD proactively might add time and complexity to an already lengthy preoperative workup, its importance cannot be underestimated. Failure to do so could potentially result in a trio of adverse outcomes: (1) unsatisfactory vision (eg, refractive misses, fluctuating vision, induced higher-order aberrations); (2) new or worsened OSD symptoms (eg, foreign-body sensation, redness, pain); and (3) postoperative infection such as endophthalmitis. Our new management algorithm aims to sensibly guide the preoperative patient encounter to avoid these postoperative complications.

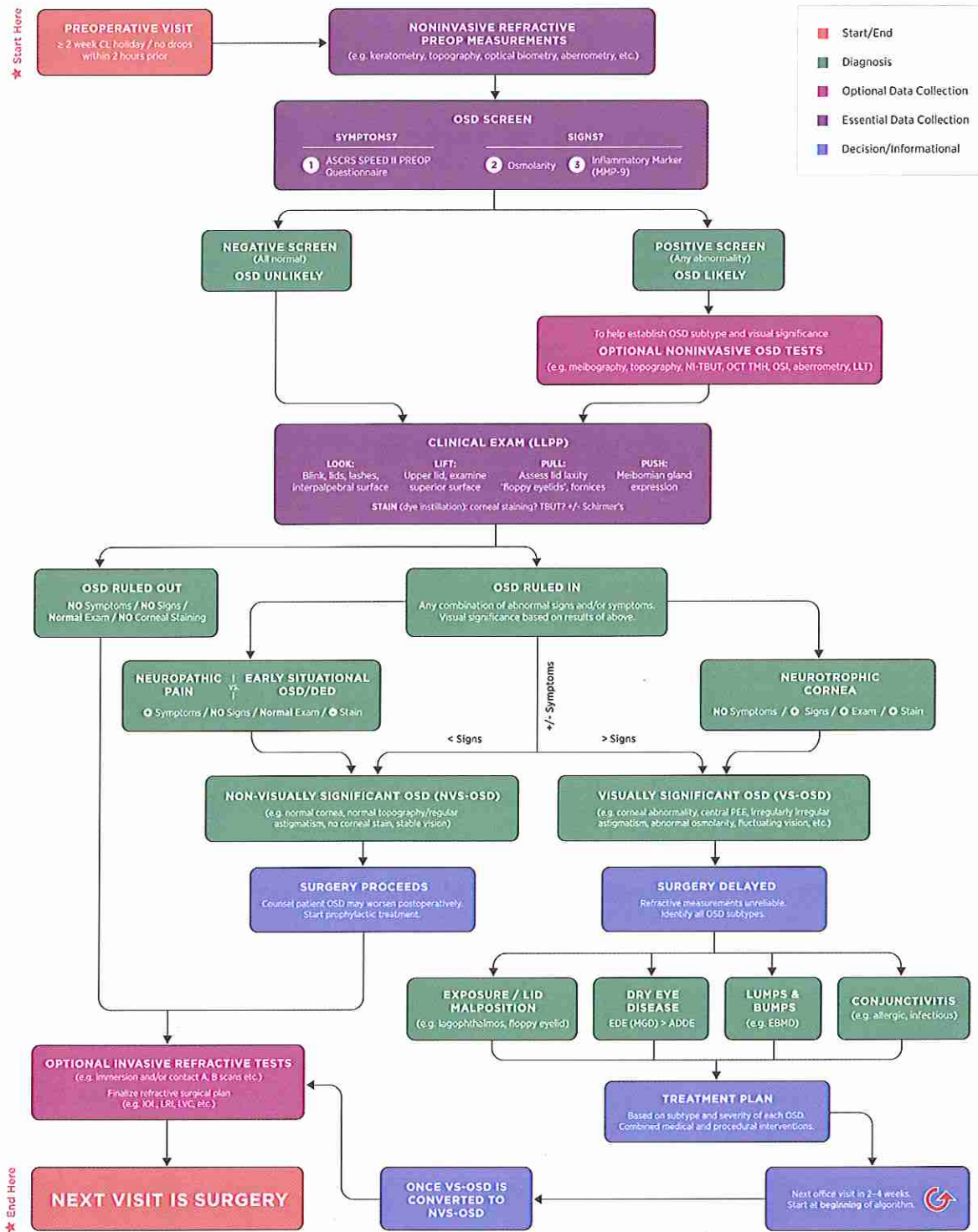
The preoperative OSD algorithm and preoperative OSD questionnaire developed by the ASCRS Cornea Clinical Committee are included as [Figure 1](#) and [Figure 2](#) of this article, and also were included in the polybag with this issue of the JCRS.

CME ITEMSON OVERVIEW OF THE PREOPERATIVE OSD ALGORITHM

Although any corneal or lens-based surgery today could reasonably be considered *refractive* because most patients will expect improved vision afterward, we designed our algorithm primarily for lens-based and corneal-based refractive surgeries, cataract and LASIK being the most common. These surgeries typically involve the highest visual expectations of spectacle independence, require highly precise preoperative refractive measurements, and typically also involve significant patient costs for noncovered services. Nonetheless, the general principles and methodology of the algorithm could reasonably apply to any patient encounter in which DED or OSD is suspected. Moreover, although our algorithm ([Figure 1](#)) is designed for integration into the preoperative visit (ie, the last office visit before surgery is performed), we recommend clinicians attempt to identify and treat significant OSD as early as possible, ideally at previous visits, using the same diagnostic methodology. Because preoperative refractive surgery visits already involve significant, often technician-driven, refractive and biometric testing, we created the algorithm with an emphasis and reliance on technician-performed objective noninvasive point-of-care testing, which saves the physician time, is educational for patients, and is not disruptive to the ocular surface, cornea, or tear film.

Several published algorithms exist for symptomatic DED and/or DTS in routine patients; however, to our knowledge, ours is the first presurgical-specific algorithm for diagnosing all OSDs before refractive surgery. We acknowledge that DED, in particular evaporative DED (E-DED), is the most common subtype of OSD, but many other non-DED subtypes of OSD can also have a negative impact on vision and postoperative visual outcomes. Thus, our algorithm was designed to identify any form of OSD before surgery, regardless of the presence of suggestive symptoms. Many non-DED subtypes of OSD can masquerade as DED with overlapping symptomatology; however, if the symptoms are misdiagnosed or mistreated as DED, they will likely worsen with time and from surgery, and lead to unsatisfactory postoperative vision.

ASCRS PREOPERATIVE OSD ALGORITHM



©ASCRS 2019



Figure 1. The ASCRS preoperative OSD algorithm (ADDE = aqueous-deficient dry eye; CL = contact lens; DED = dry-eye disease; EBMD = epithelial basement membrane dystrophy; EDE = evaporative dry eye; IOL = intraocular lens; LLPP = Look, Lift, Pull, Push; LLT = lipid layer thickness; LRI = limbal relaxing incisions; LVC = laser vision correction; MGD = meibomian gland dysfunction; MMP-9 = matrix metalloproteinase-9; NI-TBUT = noninvasive tear breakup time; NVS-OSD = nonvisually significant ocular surface disease; OCT = optical coherence tomography; OSD = ocular surface disease; OSI = ocular scatter index; SPEED = Standard Patient Evaluation of Eye Dryness; TBUT = tear breakup time; TMH = tear meniscus height; VS-OSD = visually significant ocular surface disease).

Symptom assessment will always be an integral part of any OSD diagnostic protocol. Unlike others, however, our algorithm proceeds even in the absence of OSD symptoms. Many patients, especially older patients with significant cataracts, either do not have OSD symptoms or do not feel compelled to report them, leading to normal results of traditional validated DED questionnaires, such as the Ocular Surface Disease Index (OSDI) or Standard Patient Evaluation of Eye Dryness (SPEED). The signs and symptoms of DED have long been known to be poorly correlated, and studies^{6,7} have shown this disparity can be even more significant in older preoperative cataract surgical patients who are often asymptomatic despite having advanced signs of OSD. Although we believe it is important to identify and address all subtypes of OSD in each preoperative patient, not every subtype of OSD requires delaying refractive measurements and surgery. Postponing a planned surgery date can be highly disruptive and costly to patients and surgeons alike; thus, we strive to limit this course of action to only those cases of OSD that are likely to lead to adverse postoperative outcomes. Toward this goal, our algorithm introduces new terminology for classifying any OSD into two important presurgical categories: nonvisually significant OSD (NVS-OSD) and VS-OSD. Examples of NVS-OSD could include diagnoses such as early, preclinical, or situational DED; mild conjunctivochalasis with a normal tear film; nonobvious meibomian gland disease; pinguecula; and neuropathic corneal pain syndrome, among many others. Although final refractive measurements and surgery can proceed as planned, patients with NVS-OSD should be educated about their conditions and counseled about the potential for worsening after surgery. Prophylactic treatment should be initiated preoperatively and continued postoperatively to minimize the risk for OSD exacerbations.

VS-OSD, via multiple potential mechanisms, leads to reduced visual quality and potential errors in preoperative measurements (topography, keratometry, refraction, aberrometry). Any OSD that results in corneal staining or hyperosmolarity (eg, DED, meibomian gland disease [MGD], neurotrophic or exposure keratitis, etc.) and/or irregular astigmatism (eg, epithelial basement membrane dystrophy [EBMD], pterygium, Salzmann nodules, etc.) and/or increases the risk for surgical infection (eg, infectious conjunctivitis, staphylococcal blepharitis, etc.) would be deemed as VS-OSD. When VS-OSD is identified by the preoperative algorithm via the combination of symptoms, objective tests, and a physical examination, we recommend postponing surgery and delaying the final refractive measurements until it is fully treated and resolved. At each follow-up, the algorithm should be repeated from the beginning until the VS-OSD is converted to NVS-OSD, at which time the final measurements can be performed and surgery can proceed.

CME ITEMSALGORITHM PART 1: OSD SCREEN (SIGNS AND SYMPTOMS)

Symptoms: A Novel Preoperative OSD Questionnaire

Similar to other diagnostic protocols, ours starts with a standardized symptom questionnaire. Assessing patient

symptomatology in a systematic manner is important before any surgery. OSD is often multifactorial and the severity of symptoms is variable, depending on the environment, activity stressors, and disease severity. To our knowledge, none of the published validated DED questionnaires were created specifically with the preoperative patient in mind. Well-established questionnaires, such as the OSDI^{13,14} and 5-Item Dry Eye Questionnaire,¹⁵ which are recommended in the TFOS DEWS II DED algorithm,¹⁶ as well as the SANDE (Symptom Assessment iN Dry Eye)¹⁷ and SPEED questionnaires,^{18,19} although useful for DED in a general population, do not address the specific concerns of a preoperative population. With permission from Johnson & Johnson Vision, Inc., we amended their validated SPEED questionnaire to include extra questions relevant to identifying OSD in preoperative patients. The SPEED questionnaire was shown to have a good correlation between ocular surface staining and clinical measures of meibomian gland function.¹⁹ It comprises questions related to frequency and severity of eye irritation (dryness, soreness, burning, fatigue), and it assesses impairment of daily activities. The validated numerical scoring system of SPEED is useful for identifying and grading the severity of DED-related symptoms, and it was validated against the OSDI (mean scores of ≤ 2 = asymptomatic, 5 = mild, 6.6 = moderate, 9.9 = severe DED).²⁰ The total score (X/28) should be tallied by a technician or other office staff and recorded at the bottom of the page for quick reference. This validated numerical scoring system has been retained in our ASCRS-modified Preoperative OSD SPEED II questionnaire, the first designed specifically for preoperative refractive surgery patients (Figure 2). In addition, we have included extra questions to help screen for other subtypes of OSD (blepharitis, allergic conjunctivitis, contact lens-related); visual significance (fluctuating vision, improvement with blinking or lubricants); and potential infection risk (styes, crusting of lashes, eyelid irritation, blepharitis). Last, because patient expectations, desire for spectacle independence, willingness to pay out-of-pocket fees for noncovered services, and self-ascribed personality type (easygoing to perfectionist) can all guide preoperative treatment decisions, we have adapted these items with permission from Dr. Steven Dell's Cataract & Refractive Lens Exchange Questionnaire.^A Although our additional questions to SPEED do not have a validated scoring rubric, the number of checked red boxes can be tallied by a technician and recorded at the bottom of the page for easy reference (X/18). The higher total number of red boxes (ie, red flags) and higher total SPEED scores should raise the suspicion for VS-OSD and the likely need for a custom, multifaceted, aggressive preoperative treatment regimen.

Signs: Objective Noninvasive Tear Testing

After the questionnaire is completed and independent of its findings, the technician can proceed with noninvasive objective testing, first for refractive and IOL measurements (eg, noncontact optical biometry, keratometry, tomography, topography, aberrometry) and second for objective



SPEED II® PREOP OSD QUESTIONNAIRE

Dry Eye Disease is a common reason that patients visit eye doctors, and it can have an impact on surgical outcomes. Please take a moment to thoughtfully complete the questionnaire.

Patient Name: _____

Date: _____

1. Report the **FREQUENCY** of your symptoms using the rating list below:

SYMPTOMS	0	1	2	3	0 = Never 1 = Sometimes 2 = Often 3 = Constant
Dryness, Grittiness or Scratchiness					
Soreness or Irritation					
Burning or Watering					
Eye Fatigue					

2. Report the **SEVERITY** of your symptoms using the rating list below:

SYMPTOMS	0	1	2	3	4	0 = No problems 1 = Tolerable – not perfect but not uncomfortable 2 = Uncomfortable – irritating but doesn't interfere with my day 3 = Bothersome – irritating and interferes with my day 4 = Intolerable – unable to perform my daily tasks
Dryness, Grittiness or Scratchiness						
Soreness or Irritation						
Burning or Watering						
Eye Fatigue						

3. Please check if you have experienced above symptoms:

Today Within last 3 days Within past 3 months

Do you use eye drops for lubrication? Yes No If yes, how often? _____

Do you have fluctuating vision? Never Sometimes Frequently Always

If yes, does the fluctuating vision improve with blinking and/or lubricating drops? Yes No

Have you been told you have *blepharitis*? Yes No

Have you been treated for a *stye*? Yes No

Have you had any of these symptoms recently? Eyelid redness Crusting around lashes Lid irritation

Do you wear contact lenses? Yes No

If yes, when was the last time you wore them? _____

If yes, do your eyes feel worse when they're on? Yes No

Do your eyes itch? Never Sometimes Frequently Always

If yes, do you have known environmental allergies or allergic conjunctivitis? Yes No

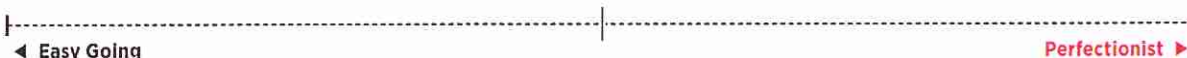
Are your ocular symptoms symmetric between both eyes? Yes No

If no, which eye is the most symptomatic? Right Left

Do you mind wearing glasses and/or contact lenses for improving your vision? Yes No

If yes, would you be willing to pay out-of-pocket costs to reduce or eliminate your dependence on them? Yes No

Please place an "X" on the following scale to describe your personality as best you can:



For office use only: **Total Speed Score** (Frequency + Severity) = _____ / 28 Number of **Red** boxes checked = _____ / 18

Figure 2. ASCRS SPEED II preoperative OSD questionnaire (OSD = ocular surface disease; SPEED = Standard Patient Evaluation of Eye Dryness).

signs of OSD. Despite a wide variety of currently available point-of-care OSD diagnostic tests, the ASCRS Cornea Clinical Committee recommends the initial essential screening battery to include assessments of both tear osmolarity and tear inflammation (MMP-9). These two point-of-care tests are widely available, relatively inexpensive, rapidly and easily performed by trained technicians, and have favorable sensitivity and specificity in the diagnosis of DED. It is important that patients not apply eyedrops within 2 hours before testing of either tear osmolarity or MMP-9 because this might alter the accuracy.

Essential Screening Tests: Osmolarity and MMP-9

Tear hyperosmolarity is central to the modern definition of DED.²¹ In the United States, the TearLab Osmolarity System (TearLab Corp.) is a U.S. Food and Drug Administration (FDA)-approved device that can perform the Clinical Laboratory Improvement Amendments (CLIA)-waived in-office test of tear osmolarity and can be easily integrated into a routine workflow. A microchip test card is placed in the lower lateral tear meniscus to collect a 50 nL tear sample. This tool has been shown to be a valid and reliable way to assess tear osmolarity.^{22,23} An osmolarity value greater than 307 mOsm/L has been identified as the most sensitive threshold to differentiate between normal and mild-to-moderate DED patients.²² Osmolarity is also considered abnormal if there is an intereye difference greater than 7 mOsm/L. In general, mild-to-moderate DED is typically diagnosed at a mean osmolarity of 315 mOsm/L, and severe DED has a mean value of 336 mOsm/L. Intereye variability and day-to-day variability have also been shown to correlate with increasing DED severity.²⁴

MMP-9 is an enzyme that is released during an inflammatory response, and it plays a role in ocular surface breakdown. It was found to be elevated in patients with different types of OSD, including Sjögren syndrome and MGD.²⁵ In-office testing of MMP-9 is currently possible with Inflammadry (Quidel Corp.); this CLIA-waived test has an 85% sensitivity and 94% specificity.^{26,27} The testing applicator is applied against the palpebral conjunctiva to collect the tear sample, and within 10 minutes, the test is positive if 40 ng/mL or more of MMP-9 is detected. MMP-9 testing can help guide OSD treatment. Identification of elevated MMP-9 suggests a patient would likely benefit from anti-inflammatory therapy, such as topical corticosteroids and/or topical lifitegrast or cyclosporine.²⁸ As a general rule, the ASCRS Cornea Clinical Committee recommends refraining from punctal occlusion for DED until ocular surface inflammation (MMP-9) is normalized because this could worsen patient symptoms.

The combination of osmolarity and MMP-9 screening tests has been shown to be valuable in identifying OSD in asymptomatic preoperative cataract surgery patients.⁷ In addition, the various combinations of screening symptoms, osmolarity, and MMP-9 can be used together to infer potential diagnoses of OSD. In a study of symptomatic patients with normal tear osmolarity,⁸ the most common non-DED diagnoses included anterior blepharitis (26%),

allergic conjunctivitis (21%), corneal EBMD (8%), contact lens intolerance (6%), conjunctivochalasis (5%), keratoneuralgia (4%), and computer vision syndrome (4%). If a patient is symptomatic and has abnormal osmolarity and elevated MMP-9, then inflamed-DED is highly likely and should be treated appropriately. Because MMP-9 is a nonspecific inflammatory marker, when elevated, especially when osmolarity is normal, other non-DED OSD subtypes that can lead to inflammation (eg, pterygium, allergic conjunctivitis, EBMD, recurrent corneal erosion syndrome, ocular rosacea, anterior blepharitis, conjunctivochalasis, and autoimmune diseases such as Sjögren syndrome and thyroid disease) should be ruled out.²⁹⁻³⁴ MMP-9 positivity has also been shown to increase with increasing severity of meibomian gland obstruction as well as with the degree of corneal staining.^{32,35,36} Therefore, if the MMP-9 screening test is positive, the clinician should carefully rule out potentially visually significant corneal staining preoperatively. In patients with symptoms but no signs on the screening tests, a diagnosis of neuropathic corneal pain should be considered, especially when the slitlamp evaluation is normal. Conversely, in patients with no symptoms but significant signs of OSD, neurotrophic keratitis should be considered and treated preoperatively.

If any one of the three components of the initial screening battery are abnormal, then the presurgical patient is at risk for OSD, and further diagnostic tests can be done to identify OSD subtypes. These extra diagnostic tools can be divided into noninvasive and invasive tests. The ASCRS Cornea Clinical Committee consensus is that noninvasive tests are preferable, if available, because the ocular surface, cornea, and tear film are not disrupted. Although not essential to the fundamental algorithm, objective tests for lipid layer thickness (LLT), meibography, noninvasive tear breakup time (NI-TBUT), quantification of tear meniscus height (TMH), tear lactoferrin levels, topography/tomography, aberrometry and ocular scatter index (OSI) can be useful adjuncts in determining OSD and DED subtypes as well as in assessing their visual significance.

Optional Noninvasive Objective OSD Tests

Meibomian Gland Imaging, LLT, and NI-TBUT The stability of the precorneal tear film is dependent on the health of the meibomian glands. A reduced TBUT can alter visual function and lead to symptoms of OSD. As MGD progresses and becomes chronic, the meibomian glands begin to dilate, become tortuous, and eventually atrophy. Meibomian gland imaging can be used clinically to identify gland atrophy and stage disease severity; this information can help the clinician to anticipate response to treatment. The multipurpose corneal topographer (Keratograph 5M, Oculus, Inc.) uses infrared light to obtain surface images of the meibomian glands. By contrast, two meibography interferometers (LipiView II and LipiScan, Johnson & Johnson Vision, Inc.) use dynamic surface illumination and adaptive transillumination to provide high-definition images of the meibomian glands. In addition to quantifying blink rates and blink quality, the LipiView can also measure

the LLT of the precorneal tear film. LLT has been correlated with the number of expressible glands present. An LLT lower than 60 nm has been shown to have 90.2% specificity for the presence of MGD.³⁷ The multipurpose corneal topographer can also measure NI-TBUT without the need for vital dyes, unlike the traditional invasive methods (TBUT). The device obtains thousands of datapoints from Placido rings projected onto the tear film. The change in the ring image identifies areas within the tear film that are breaking up, and the time in which this occurs is reported. This test can be used to diagnose an unstable tear film and can be followed over time. An autorefractor keratometer device (RT-7000, Tomey Corp.) can also perform NI-TBUT using its tear stability analysis system.

Corneal Topography and Ocular Scatter Most Placido ring-based corneal topographers can be used as screening tools to identify possible VS-OSD in addition to assessing corneal astigmatism and surface regularity. Data might be absent or mires irregular when the ocular surface is dry or in the setting of anterior basement membrane dystrophy or pterygium. An “irregularly irregular” topographic pattern, especially when highly variable between tests, is highly suggestive of DED in the absence of causative corneal lesions. In addition, many topographers provide quantifiable irregularity indices, which when elevated, can potentially signify a VS-OSD. An optical quality analysis device (HD Analyzer, Visiometrics SL) employs a double-pass technique as light passes through the ocular interfaces to measure forward scatter resulting from localized deviations of light. The measurements are objective and noninvasive and do not require any subjective component from the patient or examiner. The OSI can be used to objectively assess the visual significance of cataracts and the ocular surface and tear film separately, and it can provide useful measures of visual quality and performance rather than simple Snellen acuity.³⁸ Measuring changes in the OSI between blinks can objectively quantify the effect of the tear film on visual quality as well as measure NI-TBUT. An increase in OSI between blinks suggests VS-OSD, and it should be addressed preoperatively.

The multipurpose corneal topographer also has the ability to objectively measure the TMH, as do many high-resolution optical coherence tomography devices, which are readily available in many offices. Objective and noninvasive quantification of the TMH and volume can be useful in differentiating between primarily aqueous-deficient DED (AD-DED) and E-DED subtypes, a distinction that neither osmolarity nor MMP-9 testing can make. These noninvasive no-touch measures of tear production are preferable to more invasive tools (eg, Schirmer testing) in preoperative refractive patients.

Sjögren Disease Antibody Testing Traditional laboratory testing for Sjögren disease includes Sjögren-specific antibody A and Sjögren-specific antibody B, in addition to antinuclear antibody and rheumatoid factor testing. Early detection of Sjögren disease is important because it can be associated with systemic diseases such as lymphoma, lupus, sclerosis, and other autoimmune conditions.^{39,40}

Antibody testing should be considered in any patient with signs of significant AD-DED and symptoms of dry eyes, skin or mouth, joint aches, fatigue, and/or dental problems. Sjögren syndrome is more common in females, but it occurs in males as well. In younger preoperative keratorefractive surgery patients with suggestive symptoms and abnormalities in osmolarity and/or MMP-9, Sjögren disease should be ruled out. Similarly, in older preoperative cataract patients, since the diagnosis is often delayed by many years, Sjögren disease should be ruled out in those with suspicious systemic symptoms and an abnormal preoperative OSD screen. Although a point-of-care CLIA class II test for the quantification of tear lactoferrin levels exists (Tearscan System, Advanced Tear Diagnostics, LLC), no member of the ASCRS Cornea Clinical Committee has used it in clinical practice. However, if the device is available, abnormally low levels of tear lactoferrin can be associated with AD-DED and Sjögren syndrome.⁴¹ A diagnostic laboratory panel (Sjö, Bausch & Lomb, Inc.) can be used to test for traditional and novel proprietary biomarkers for the early detection of Sjögren syndrome. The three proprietary markers are: (1) salivary protein-1 (SP-1, immunoglobulin A [IgA], immunoglobulin G [IgG], immunoglobulin M [IgM]); (2) carbonic anhydrase-6 (CA-6, IgA, IgG, IgM); and (3) parotid secretory protein (PSP, IgA, IgG, IgM). These markers increase sensitivity and specificity for early detection.^{42,43} This in-office test is easy to adopt in an ophthalmic practice; blood can be drawn by finger stick and applied to a card or drawn in a vial and can then be sent for analysis.

CME ITEMSALGORITHM PART 2: CLINICAL EXAMINATION

Look, Lift, Pull, and Push Examination

Despite the use of the aforementioned noninvasive objective screening tests, no preoperative clinical assessment is complete without a physical examination. Although this portion of the algorithm is performed regardless of whether the screening battery was positive (OSD likely) or negative (OSD unlikely), 70% of the ASCRS Cornea Clinical Committee members feel comfortable allowing a trained physician extender (eg, technician or physician assistant) to perform this step. We recommend a quick focused ocular surface examination, dubbed Look, Lift, Pull, Push, to confirm the subtype, severity, and visual significance of any present OSD.

Look: Look at the blink quality and quantity; examine the eyelids for malposition, lagophthalmos, proptosis and exposure, entropion or ectropion, and trichiasis; and then visually assess the TMH. Look for signs of anterior and posterior blepharitis (scurf, collarettes, foamy tears, cylindrical dandruff, Demodex mites, bacterial overgrowth, biofilm, keratinization, telangiectasias, meibomian gland capping, chalazia, lid margin pitting, etc.). Look at the interpalpebral ocular surface for signs of conjunctival injection, follicles and papillae, discharge and mucus, concretions, conjunctivochalasis, pingueculae, pterygia, and conjunctival scarring and symblepharon. Look at the interpalpebral

cornea for any surface abnormality; loss of clarity; lumps and bumps including pterygia, subepithelial scarring, Salzmann nodules, and filaments; and anterior dystrophies including subtle EBMD. In some cases, punctate epithelial erosions and superficial punctate keratitis can be seen under direct illumination without dyes and stains.

Lift and Pull: Lifting up and then pulling out of the upper eyelid is an often overlooked portion of the ocular surface examination. Although superior limbic keratitis and superior corneal scars can be detected, the main reasons for lifting then pulling the upper lid are to rule out superior EBMD and to identify eyelid laxity and floppy eyelid syndrome. Both superior EBMD and floppy eyelid syndrome are very common, often missed, and can be visually significant preoperatively and postoperatively.

Push: By pushing on the lower lid margin, the meibomian glands are expressed and the quality, quantity, and flow of the meibum are assessed.⁴⁴ This can easily be accomplished using a finger, a cotton-tipped applicator, or a more formal device such as a meibomian gland evaluator (Korb, Johnson & Johnson Vision, Inc.), which applies about 1 g/mm² to the area in contact with the device to simulate the pressure generated with a normal blink. Gland expression can be particularly helpful in identifying patients with nonobvious MGD, a form of obstructive MGD in which classic inflammatory signs are absent.⁴⁵

At this stage in the algorithm, symptoms have been assessed, baseline refractive measurements and noninvasive OSD tests have been completed, and the ocular surface has been examined for evidence of OSD. If no further refractive or preoperative measurements are required for surgical planning, the final phase of the algorithm can be initiated. This involves invasive testing, most importantly, corneal staining and TBUT, which can help distinguish between NVS-OSD and VS-OSD, but after which precise and reliable refractive measurements cannot be performed.

Vital Dye Staining

Sodium fluorescein is a nontoxic dye commonly used to assess tear-film stability and can also stain any epithelial defects. It can be applied in a solution or in an impregnated strip form. Generally, the strips apply a more controlled amount of dye, allowing better visualization of the corneal surface. The dye mixes with the precorneal tear film, and a cobalt blue light is used to illuminate the stained surface. The time of initial breakdown of the tear film or first appearance of any hypofluorescent area is the TBUT. In general, less than 10 seconds of TBUT is considered abnormal. The TBUT can be used to monitor DED status and response to therapy; it has been used for many years because of ease of integration into clinical practice. Rose bengal dye is a derivative of fluorescein that stains devitalized cells.⁴⁶ It can also be used in a solution or impregnated strip form, but some ocular discomfort after instillation can occur. Rose bengal and other dyes such as lissamine green can be used to detect DED earlier in the disease course because conjunctival staining might be present earlier than corneal staining.^{47,48} After the instillation of vital

dye, with or without anesthetic, aqueous tear production can be optionally assessed with a traditional Schirmer test or phenol red thread test. However, most ASCRS Corneal Clinical Committee members have largely abandoned these tests. Of note, when moderate-to-severe corneal staining is detected, especially if minimal symptoms are present, the clinician should consider a diagnosis of neurotrophic keratitis. Corneal sensation testing can be an adjunctive test to establish altered sensation.

Visually Significant Versus Nonvisually Significant Ocular Surface Disease

At this point in the algorithm, the clinical investigation and data collection are complete. The final determination of the magnitude of the visual significance of OSD is ultimately at the discretion of the surgeon and is arrived upon by a careful synthesis of the results of the questionnaire, objective tests, and clinical examination with subsequent dye staining. *Visual significance* implies a potential direct adverse effect on visual quality and Snellen acuity, not only preoperatively, but postoperatively as well. In addition, visual significance also pertains to the likelihood that the identified subtypes and severity of the OSD will lead to imprecision of presurgical measurements resulting in refractive misses and residual ametropia. Any combination of fluctuating vision improved with blinking or lubrication, highly elevated osmolarity and MMP-9, irregularly irregular fluctuating topography and/or aberrometry, interblink increases of OSI, irregular astigmatism from corneal epithelial abnormalities, and significant corneal staining would all be considered visually significant. Last, visual significance also refers to the potential of the identified OSD leading to a postoperative infection, endophthalmitis being the most significant. Bacterial-associated subtypes of OSD—such as staphylococcal blepharitis, bacterial biofilms, and infectious conjunctivitis—should be identified and treated fully cooperatively. In any case of VS-OSD, the preoperative refractive measurements and surgery itself should be postponed until the VS-OSD is sufficiently treated and converted to NVS-OSD. In cases where OSD is identified but deemed nonvisually significant, surgery can proceed as planned, but the patient should be educated about his or her condition and prophylactically treated to prevent postoperative worsening.

By consensus of the ASCRS Cornea Clinical Committee, the treatment of OSD, especially VS-OSD, in the preoperative patient population generally requires a more aggressive, often multifaceted approach with a targeted combination of prescription medications and procedural interventions to rapidly reverse OSD and to minimize surgical delays.

CME ITEMSALGORITHM PART 3: TREATMENT BASED ON SUBTYPES AND SEVERITY OF OSD

Although the recommended guidelines by the TFOS DEWS II report in 2017⁴⁹ are a great tool to aid clinicians in treatment considerations for DED, the treatment approach in the presurgical patient has some unique considerations. Specifically, in the preoperative cataract or corneal

refractive evaluation, if VS-OSD is diagnosed, treatment should be initiated at a higher, more advanced level. This is attributable in part to the need for rapid restoration of tear-film homeostasis to optimize preoperative measurements as well as to maximize postoperative outcomes and patient satisfaction. As such, a monotherapy approach and a waiting period to monitor for the addition of further therapy are often not sufficient to create a rapid turnaround of the tear-film homeostasis in this setting. Tear-film inflammation, lid margin disease, and ocular surface staining should be addressed simultaneously to achieve a rapid improvement in preparation for surgery.

With the goals of minimizing surgical delays, maximizing preoperative measurement confidence, and reducing postoperative complications, treatment options in the preoperative setting should minimally start at Step 2 of the TFOS DEWS II treatment guidelines. Step 1 treatments such as artificial tears and lubricants, warm compresses, lid hygiene, and nutritional supplements are reasonable adjuncts but often insufficient to rapidly reverse VS-OSD. A combination of medical and procedural interventions based on disease subtype and severity will dictate the best approach in the preoperative patient. Because DED is becoming more widely recognized as a multifactorial disease involving tear composition, ocular surface inflammation, and lid margin disease, there are increasingly more treatment approaches available.

Antiinflammatory Treatments

Given that both AD-DED and E-DED lead to a loss of tear homeostasis and ultimately inflammation, antiinflammatory treatments are often beneficial.^{50,51} Rapid and potent antiinflammatory effects can be achieved with a pulse of topical steroids. Although topical steroids have immediate effectiveness in decreasing tear-film inflammatory cytokines, their long-term use is limited because of known side effects. In the preoperative setting, where rapid rescue and improvement of the ocular surface is required, steroids could play an important role. Clinicians can therefore have a lower threshold for initiation of steroids in cataract and refractive surgery candidates with OSD than they would for other patients with DED. Studies^{52,53} have shown that the use of loteprednol etabonate 0.5% and fluorometholone demonstrate significant effects in improving signs and symptoms of DED. These studies found no significant steroid-related complications over a short 4-week course. As a rescue treatment and in pulsed dosing perioperatively, steroids can have a positive and rapid effect on the ocular surface. In addition, a 4- to 6-week course of a topical steroid, such as loteprednol, might help improve tolerability of other treatments with adverse effects such as burning and increased ocular surface sensitivity.⁵⁴

Prescription topical antiinflammatory drugs, such as cyclosporin A (CsA) and lifitegrast, have been shown to be effective in the long-term management of DED.⁵⁵⁻⁵⁷ CsA, which is a fungal-derived peptide, has been known to affect DED by its specific immunosuppressive and antiinflammatory effects. The decreased release of inflammatory

cytokines, such as interleukin-2 and interferon gamma, through inhibition of T-cell activities are among its main sources of action.⁵⁸ Multiple studies comparing various dosing concentrations^{55,59} concluded that in the 0.05% and 0.1% formulations, there was consistent improvement in subjective patient symptoms as well as an objective decrease of vital dye staining of the ocular surface and an increase in Schirmer scores. Significant increases in goblet cell density of the ocular surface has also been observed with CsA use.⁶⁰ CsA 0.05% used twice daily with an adjunctive topical corticosteroid was effective in managing dry eye in the cataract setting, with symptomatic and clinical amelioration in as few as 2 weeks.⁶¹ Lifitegrast, which was approved by the FDA in 2016 for the treatment of DED signs and symptoms, might have an advantage in the preoperative setting because of its more rapid onset of action. Topical lifitegrast is the first choice immunomodulator in the preoperative setting of 70% of the ASCRS Cornea Clinical Committee members. Although we recommend instituting topical immunomodulator therapy as far in advance of surgery as possible, a minimum of 2 to 4 weeks prior should have a beneficial impact on the ocular surface. In two phase 3 studies with more than 700 patients each,^{56,57} lifitegrast showed a significant improvement in eye dryness compared with vehicle as early as 2 weeks after starting treatment. In addition, a significant decrease in inferior corneal staining was observed at week 12.^{57,62} Lifitegrast works by blocking the interaction between intracellular adhesion molecule-1, which is upregulated on the ocular surface of DED patients, and lymphocyte function-associated antigen-1 on the T-cell. Lifitegrast thereby inhibits the migration and binding of T-cells to the ocular surface and their activation and release of cytokines. It is postulated that its more rapid onset of action is because of its multitarget action on the inflammatory cycle and its ability to turn off already active T-cells.⁶³

When there is significant ocular rosacea and lid margin inflammation, oral tetracyclines can be used. Doxycycline is particularly useful, not only for control of deleterious free fatty acids and bacterial overgrowth, but also for its inhibition of tear-film cytokines including MMP-9.⁶⁴ This class of drugs works by a dual mechanism of action. Primarily, tetracycline derivatives work by decreasing the bioactivity of many cytokines in the inflammatory pathway including interleukin-1, tumor necrosis factor- α and MMP-1, MMP-3, and MMP-9.^{65,66} By decreasing MMP-9 in the corneal epithelium, these drugs improve the integrity of the tight junctions between cells, thus improving the barrier function of the epithelium and decreasing cell apoptosis.⁶⁷ The antimicrobial effects of the tetracycline analogs are also thought to play a role in alleviating bacterial lid margin disease. The secondary antibiotic effect can decrease bacterial lid flora with a resultant decrease in lipolytic enzymes and meibomian lipid breakdown products.^{67,68} This might have an additional benefit of minimizing the risk for lid margin and blepharitis-related postoperative infection and endophthalmitis. Several studies using oral tetracycline derivatives⁶⁷⁻⁷⁰ have

described significant improvement in signs and symptoms of chronic lid margin and DED. These oral tetracyclines are often prescribed for a 1- to 2-month course and can be repeated as a pulse therapy 2 to 4 times per year. In the preoperative setting, even a 1-month course might help with reducing inflammation and bacterial load before surgery.

Lid Margin Disease Treatments

The treatment of MGD and anterior blepharitis is particularly important before intraocular surgery. Relieving the chronic stasis and obstruction in the meibomian glands is essential to the successful treatment of MGD and improvement in DED symptoms.^{71,72} Blepharitis is a common cause of cataract surgery cancellation and is a major risk factor for postoperative endophthalmitis.⁷³ MGD treatment can be initiated with regular warm compresses and lid hygiene at home. However, compliance can be low and expression of glands at home is often difficult to perform adequately, especially in the elderly. Bacterial blepharitis should be treated with the use of regular lid cleansing products. Anti-infective therapies, such as antibiotic ointments and lid scrubs, should be initiated more aggressively in the preoperative setting to manage lid margin bacterial overgrowth. Hypochlorous acid solutions to clean the lid margin have also been shown to significantly decrease biofilm of the lid margin and can be of benefit for preoperative lid margin disinfecting.⁷⁴ In confirmed or suspected cases of Demodex mite infection, lid scrubs with a tea tree oil component should be initiated.⁷⁵ Mechanical blepharoexfoliation (BlephEx, LLC) of the lid margin in cases of significant anterior blepharitis with biofilm, scurf, collarettes, and/or debris is a quick procedural adjunct in the preoperative setting for rapidly reducing infectious loads, reducing bacterial and biofilm resistance, and likely decreasing the risk for postoperative infections.⁷⁶

Because warm compresses used at home often do not reach adequate temperatures for sustained periods, the use of in-office thermal pulsation treatments can be offered to preoperative patients for more rapid efficacy. A thermal pulsation device (LipiFlow, Johnson & Johnson Vision, Inc.)—a 12-minute automated procedure for heating, massaging, and expressing of the meibomian glands—can be used in-office and is the favored preoperative MGD procedural treatment of over 80% of the ASCRS Cornea Clinical Committee members.⁷⁷ Thermal pulsation applies constant heat and a sequence of pressure pulsations that help evacuate the meibomian glands of static oils and improves glandular flow. The heat is directed immediately over the meibomian glands and avoids going through the anterior skin of the eyelid, thereby reducing the skin irritation and vascular inflammation experienced by some patients with at-home hot compresses. In this way, the temperature is also maintained, and heat is not lost before reaching the glands. In a trial comparing a single thermal pulsation device treatment ($n = 69$) to daily warm compress therapy ($n = 70$),⁷⁷ the thermal pulsation device group had significant improvement in their TBUT and symptoms at 2 weeks and 4 weeks compared with the

warm compress group. With a single treatment, the improvement in gland scores and patient-reported improvement in symptoms (OSDI and SPEED questionnaire) were maintained up to 9 months.⁷⁸ The rapid improvement of the lipid layer to this treatment makes it an ideal preoperative tool to optimize tear-film homeostasis.⁷⁹ In patients with signs of significant anterior blepharitis and MGD, a combination in-office procedure with blepharoexfoliation of all 4 eyelids immediately followed by a thermal pulsation procedure can quickly treat both conditions, and it is recommended by ASCRS Cornea Clinical Committee members in the preoperative setting. Other commercially available in-office procedures for lid margin disease include the iLux (Tear Film Innovations, Inc.) and the MiBo ThermoFlo (MIBO Medical Group).

Intense pulse light, originally developed for patients with acne or rosacea, is being used off label for the treatment of chronic MGD with evidence of improvement in some patients.⁸⁰ This technology uses bursts of light at particular wavelengths (between 500 to 1200 nm) that cause changes in the blood vessels, thereby eliminating telangiectasias and erythema of the skin. Meibomian gland probing for severe MGD has also shown benefit in restoring glandular function and improvement in symptoms in small studies.^{81,82} In the preoperative setting, these procedural treatments might be of value in certain cases for which advanced lid margin disease is the source of VS-OSD.

Increasing dietary intake of omega-3 fatty acids can also improve lid health by reducing inflammation and improving the quality of oil secretions from the meibomian glands.⁸³ Omega-3 fatty acids have been shown in a number of clinical studies to improve DED symptoms.⁸³⁻⁸⁵ Specifically, eicosapentaenoic acid and docosahexaenoic acid are long-chain polyunsaturated omega 3-fatty acids that play a role in multiorgan health. These essential fatty acids inhibit inflammatory mediators and block production of inflammatory cytokines such as interleukin-1 and tumor necrosis factor- α .⁸⁶ The large multicenter Dry Eye Assessment and Management study, which compared the effects of 3000 mg fish-derived n-3 eicosapentaenoic and docosahexaenoic acids (active supplement group) with olive oil (placebo group),⁸⁷ found no significant benefit on the ocular surface between the treatment and control groups. Despite its many strengths and compelling conclusions, limitations of the study include the lack of a true placebo group and the inclusion of patients with non-MGD-related DED. In light of this mixed evidence, 80% of the ASCRS Corneal Clinical Committee members continue to recommend dietary omega-3 supplements as adjunctive therapy for MGD and blepharitis. Its use in the preoperative setting should be left to the discretion of the clinician and the extent of lid margin disease.

Treatments to Improve Ocular Surface Staining

The consensus of the ASCRS Cornea Clinical Committee is that corneal staining is the single most critical sign of OSD that should be normalized before refractive surgery

followed by topography, TBUT, osmolarity, and MMP-9; each of which have a high likelihood of causing VS-OSD when abnormal. Aggressive lubrication with preservative-free artificial tears should be initiated when there is significant punctate staining in the preoperative setting. Preserved artificial tears, especially if used more than 4 times daily, can promote further surface irritation and corneal damage.⁸⁸ In many cases, however, artificial tears might not be sufficient to result in rapid resolution of punctate staining and more aggressive action will be required. The novel use of neurostimulation (TrueTear, Allergan, Inc.) to promote aqueous, mucin, and meibum secretion has been shown to effectively improve punctate staining and positively impact DED symptoms.⁸⁹ Its use in the preoperative patient with VS-OSD might be of value in addition to other treatments.

The use of autologous serum drops gained initial popularity in the treatment of nonhealing ocular surface erosions.^{90,91} Its effects at improving erosions led to the concept of using this biological treatment for chronic DED.⁹² The growth factors, vitamins, and antibodies present in tears are also present in blood serum drops, thus offering advantages over commercial artificial tears. In 2004, Noble et al.⁹³ compared 50% autologous serum eyedrops with standard artificial tear solutions in a prospective, randomized, controlled crossover study. Significant improvements in ocular surface cytology and vital dye staining scores were observed in the autologous serum group, whereas these effects were reversed when the treatment was reverted back to artificial tears alone. Improvements in vital dye staining, tear stability, and pain scores have also been seen in other studies comparing autologous serum to nonpreserved artificial tears.⁹⁴ The nonpreserved nature of this product does raise the concern for bacterial contamination in the preoperative setting. There is no evidence to support a higher risk for endophthalmitis with the use of autologous serum in the preoperative setting and thus its use perioperatively is left to the discretion of the clinician; 60% of the Corneal Clinical Committee members support the use of autologous serum drops in the perioperative period.

A self-retaining amniotic membrane or therapeutic bandage contact lens to address severe punctate keratitis and to restore a smooth ocular surface can be used preoperatively. Human amniotic membrane transplantation has become a popular alternative technique for several ocular surface disorders. Comprised of a single epithelium layer, a thick basement membrane, and an avascular stromal matrix, the innate properties of the amniotic membrane create an environment for wound healing and tissue regeneration when placed on the eye. Amniotic membrane transplantation has been used successfully for many severe OSDs, including ocular surface burns and Stevens-Johnson syndrome.^{95,96} The ability to place a self-retaining cryopreserved amniotic membrane (Prokera, Bio-Tissue, Inc.) has expanded its use in the clinical setting, especially in severe VS-OSD patients, such as those with neurotrophic ulcers, filamentary keratitis, DED, infectious keratitis, and

recurrent corneal erosion.^{97,98} More recently, the placement of a self-retaining cryopreserved amniotic membrane for 5 days showed an improvement in corneal nerve density as well as signs and symptoms of dry eye.⁹⁹ The Dry Eye Amniotic Membrane study¹⁰⁰ assessed the potential benefits of Prokera to treat DED. In the study, in 97 eyes of 84 patients who had the amniotic membrane transplant in place for an average of 5.4 days, 88% showed a significant improvement in the corneal staining score. A physician implants the amniotic membrane in a manner similar to the placement of a large-diameter contact lens. The use of antibiotic drops in conjunction with the device should be considered to prevent any secondary infection. Amniotic membrane extract in the form of a topical drop has also been used with success for improving the ocular surface.¹⁰¹ In preoperative patients with refractory VS-OSD, in particular those with significant corneal staining and erosions, the use of amniotic membrane therapy might facilitate more rapid resolution. The ASCRS Cornea Clinical Committee recommends continuing topical antibiotics and waiting at least 7 days between discontinuing amnion-based therapies and proceeding with intraocular surgery.

The therapeutic use of contact lenses for severe OSD cases—including corneal ulcers, persistent epithelial defects, corneal perforation, and chemical burns—has been described.^{102,103} The clinical uses for bandage contact lenses might include patients with significant corneal pain because of DED.¹⁰⁴ A soft contact lens might be used in the preoperative setting to allow epithelial healing of punctate keratitis and smoothing of the surface before preoperative biometry measurements. If the contact lenses are left in place more than 24 hours, antibiotic drops should be used to prevent any secondary infection.

Punctal occlusion has been well demonstrated in clinical practice to improve DED by increasing ocular surface moisture. This can be achieved by punctal plug placement or by punctal closure via cautery or suture placement. In the setting of inflammatory DED, however, patients with a significant increase in tear inflammatory cytokines (MMP-9) might have a negative response to plugs and experience a worsening of symptoms. These patients might benefit from managing the tear-film inflammation before punctal occlusion.¹⁰⁵

Eyelid abnormalities, including lagophthalmos, ectropion, entropion, and lid laxity, are common causes of VS-OSD. For patients with mild lagophthalmos, the combination of a nighttime gel or ointment along with a moisture goggle can be considered. Environmental modifications can have a significant impact on OSD, and education preoperatively to reduce risk factors can be valuable. The increase of environmental moisture can have a dramatic effect on symptomatology. Patients who live in dry climates are encouraged to use humidifiers. An increase in periocular humidity has been shown to increase the tear-film lipid layer, increase interblink intervals, and increase the duration of blink.¹⁰⁶ The wearing of moisture goggles or spectacles increases the periocular humidity, which can alleviate symptoms of DED.¹⁰⁷ Increased computer screen time

can also dramatically impact DED symptoms.¹⁰⁸ Modifications to screen position as well as encouragement of regular and frequent breaks for DED patients whose occupations require many hours of computer work can improve DED symptoms.¹⁰⁹

Finally, many systemic medications, such as antihistamines, might also contribute to worsening of DED. A modification of systemic medications might help to optimize the ocular surface preoperatively. If possible, systemic antihistamines should be discontinued and local antiallergy treatments initiated. Although the exact relationship of hormonal balance and DED is vague, hormonal replacement medications can be adjusted in conjunction with the patient's internist or gynecologist to ameliorate DED symptoms.¹¹⁰ In the elderly male population, a decline in androgens can trigger significant DED symptoms. Although it is not FDA-approved for DED and it requires specialty compounding, there is limited evidence that topical hormone treatment can improve DED symptoms.¹¹¹

In cases where there are superficial abnormalities of the corneal surface with topographic irregular astigmatism, such as from Salzmann nodular degeneration, pterygia, or EBMD, the surgeon might consider superficial keratectomy or pterygium excision to smooth the corneal surface before finalizing refractive measurements. After such procedural interventions, it is important to wait for refractive, astigmatic, and topographic stability as well as proper healing of the ocular surface before surgical planning is completed. Contact lens wear can also lead to corneal warpage, irregular astigmatism, and an unstable ocular surface before surgery. Most ASCRS Cornea Clinical Committee members recommend a soft contact lens holiday of at least 2 weeks before the preoperative visit, and for hard or rigid gas-permeable (RGP) lenses, at least a 1-month holiday, then waiting for topographic and keratometric stability over 2 successive visits. For long-term RGP wearers, the general rule of a 1-week holiday per decade of RGP wear is followed by the majority of ASCRS Cornea Clinical Committee members.

After initiating a multifaceted treatment regimen based on severity and subtypes of OSD, the patient can be reassessed in approximately 2 to 4 weeks. A patient who is educated preoperatively about OSD, including its impact on visual outcomes and the need to treat it aggressively, is more likely to adhere to the recommended treatment regimen. At the follow-up visit, the preoperative OSD algorithm methodology should be repeated from the beginning. If improvement in symptoms, normalization of the ocular surface, and reliable preoperative testing has been achieved, then surgical planning can be finalized at this visit. The patient should be counseled that ongoing treatment for DED must be maintained postoperatively to optimize and retain long-term visual outcomes.

CME ITEMS INTRAOPERATIVE AND POSTOPERATIVE CONSIDERATIONS

There are numerous perioperative, intraoperative, and postoperative considerations in patients with preexisting OSD who are undergoing ocular surgery. On the day of surgery, patients are usually given a series of multiple dilating, anesthetic, antiinflammatory, and antibiotic drops. These drops often contain preservatives, such as benzalkonium chloride, which have been shown to cause or exacerbate epithelial toxicity.^{112,113} Alternatively, drops with other preservatives, such as chlorobutanol, might be less toxic than benzalkonium chloride.^{112,114,115} In the operating room, the eye is prepped and draped with povidone-iodine, which can disturb the ocular surface. During the procedure, the eye is kept open with a speculum and subject to prolonged exposure. Frequent rewetting with a balanced salt solution is required. Some surgeons prefer to apply an ophthalmic viscosurgical device to the ocular surface to help keep it lubricated without the need for repetitive balanced salt solution applications. Limiting the time between the application of the speculum and the initiation of the surgery can minimize desiccation from exposure. Any surgical techniques that increase operative efficiency and decrease the length of the procedure will also limit exposure time.

Cataract surgery in general, and the creation of corneal incisions in particular, have the potential to aggravate DED.^{116,117} Surgical procedures that cause denervation of the cornea result in impaired epithelial wound healing, increased epithelial permeability, and decreased epithelial metabolic activity.^{112,116} Neuroregulation is essential to maintain the integrity of the corneal epithelium.^{112,117} Corneal sensitivity and tear production have been shown to decrease after cataract surgery.¹¹⁸ Oh et al.¹¹⁹ demonstrated a decrease in central and incisional site sensitivity for up to 1 month after cataract surgery. Longer corneal relaxing incisions used for astigmatic correction increase the risk for further denervation. One study^C demonstrated that 39% of patients with paired limbal relaxing incisions developed decreased corneal sensation for up to 3 months. Opting for a lens-based rather than an incision-based treatment of the astigmatism might limit the risk for postoperative DED. Another study¹²⁰ found femtosecond laser-assisted cataract surgery to be associated with a higher risk for corneal staining and DED symptoms when compared with conventional phacoemulsification surgery.

As part of the overall surgical plan, the postoperative eyedrop regimen should be carefully considered in patients with OSD. Postoperative drops, in particular, those with preservatives, might lead to toxicity and exacerbations of OSD. Intraocular or subconjunctival injections of antibiotics and/or steroids at the conclusion of surgery might limit or even eliminate the need for these topical medications postoperatively. In addition, there are numerous newer formulations of drops that require a lower daily dosage to achieve equal efficacy. The use of once- or twice-daily preserved drops is preferable to drops

administered 4 times daily. Topical nonsteroidal anti-inflammatory drug drops have been shown to slow corneal epithelial healing and lead to corneal melting; their use postoperatively in patients with severe OSD should be considered carefully.^{121,122}

Finally, the surgeon should continue to monitor the ocular surface closely during the postoperative course, especially in those patients who received presbyopia-correcting IOLs (eg, multifocal or accommodating). If the postoperative visual result is suboptimal, or the patient is dissatisfied, the OSD algorithm should be reinstated postoperatively and the treatment regimen should be adjusted and/or increased based on the findings. For any unhappy postoperative patient, OSD should be identified and fully treated before considering other surgical options, such as Nd:YAG capsulotomy or an IOL exchange. Patients with presbyopia-correcting IOLs might be more susceptible to visual disturbances from a poor tear film or other forms of OSD and often require close surveillance and long-term treatment postoperatively.

CME ITEMS CONCLUSION

The ASCRS Cornea Clinical Committee's suggested protocol for identifying and managing OSD in the cataract and refractive surgery patient commenced because of educational gaps found in recent annual ASCRS clinical surveys. Although over 90% of respondents felt even mild-to-moderate dry eyes affected patient satisfaction after cataract and refractive surgery, less than 10% were using currently available point-of-care diagnostic testing in their routine preoperative assessments. Our diagnostic algorithm and treatment recommendations have been specifically tailored to the preoperative refractive surgery patient who requires an accurate and efficient diagnosis of VS-OSD as well as an aggressive multifaceted treatment regimen for its rapid reversal. Incorporating the novel ASCRS Preoperative OSD Questionnaire and Diagnostic Algorithm into the preoperative visit workflow will aid refractive surgeons in optimizing preoperative measurements, improving refractive outcomes, reducing postoperative infection risk, and increasing overall patient satisfaction.

REFERENCES

- Schein OD, Munoz B, Tielsch JM, Bandeen-Roche K, West S. Prevalence of dry eye among the elderly. *Am J Ophthalmol* 1997; 124:723-728
- Nettune GR, Pflugfelder SC. Post-LASIK tear dysfunction and dysesthesia. *Ocul Surf* 2010; 8:135-145
- Naumann GO, Schlotzer-Schrehardt U. Amantadine-associated corneal edema. *Ophthalmology* 2009; 116:1230-1231; author reply 1231
- Chuck RS, Jacobs DS, Lee JK, Afshari NA, Vitale S, Shen TT, Keenan JD. American Academy of Ophthalmology Preferred Practice Pattern Refractive Management/Intervention Panel. Refractive errors & refractive surgery Preferred Practice Pattern. *Ophthalmology* 2018; 125:P1-P104
- Feder RS, Olsen TW, Prum BE Jr, Summers CG, Olson RJ, Williams RD, Musch DC. Comprehensive adult medical eye evaluation Preferred Practice Pattern guidelines. *Ophthalmology* 2016; 123:P209-P236
- Trattler WB, Majmudar PA, Donnenfeld ED, McDonald MB, Stonecipher KG, Goldberg DF. The Prospective Health Assessment of Cataract Patients' Ocular Surface (PHACO) study: the effect of dry eye. *Clin Ophthalmol* 2017; 11:1423-1430
- Gupta PK, Drinkwater OJ, VanDusen KW, Brissette AR, Starr CE. Prevalence of ocular surface dysfunction in patients presenting for cataract surgery. *J Cataract Refract Surg* 2018; 44:1090-1096
- Woodward MA, Randleman JB, Stulting RD. Dissatisfaction after multifocal intraocular lens implantation. *J Cataract Refract Surg* 2009; 35:992-997
- Epitropoulos AT, Matossian C, Berdy GJ, Malhotra RP, Potvin R. Effect of tear osmolarity on repeatability of keratometry for cataract surgery planning. *J Cataract Refract Surg* 2015; 41:1672-1677
- Gomes JAP, Azar DT, Baudouin C, Efron N, Hirayama M, Horwath-Winter J, Kim T, Mehta JS, Messmer EM, Pepose JS, Sangwan VS, Weiner AL, Wilson SE, Wolffsohn JS. TFOS DEWS II iatrogenic report. *Ocul Surf* 2017; 15:511-538
- Behrens A, Doyle JJ, Stern L, Chuck RS, McDonnell PJ, Azar DT, Dua HS, Horn M, Karpecki PM, Laibson PR, Lemp MA, Meister DM, Del Castillo JM, O'Brien TP, Pflugfelder SC, Rolando M, Schein OD, Seitz B, Tseng SC, van Setten G, Wilson SE, Yiu SC. Dysfunctional tear syndrome study group. Dysfunctional tear syndrome: a Delphi approach to treatment recommendations. *Cornea* 2006; 25:900-907
- Miner MS, Beckman KA, Luchs JL, Allen QB, Awdeh RM, Berdahl J, Boland TS, Buznego C, Gira JP, Goldberg DF, Goldman D, Goyal RK, Jackson MA, Katz J, Kim T, Majmudar PA, Malhotra RP, McDonald MB, Rajpal RK, Raviv T, Rowen S, Shamie N, Solomon JD, Stonecipher K, Tauber S, Trattler W, Walter KA, Waring GO 4th, Weinstock RJ, Wiley WF, Yeu E. Dysfunctional tear syndrome: dry eye disease and associated tear film disorders — new strategies for diagnosis and treatment. *Curr Opin Ophthalmol* 2017; 27 (Suppl 1):3-47
- Schiffman RM, Christianson MD, Jacobsen G, Hirsch JD, Reis BL. Reliability and validity of the Ocular Surface Disease Index. *Arch Ophthalmol* 2000; 118:615-621
- Ozcara F, Aydin S, Helvacı MR. Ocular surface disease index for the diagnosis of dry eye syndrome. *Ocul Immunol Inflamm* 2007; 15:389-393
- Chalmers RL, Begley CG, Caffery B. Validation of the 5-Item Dry Eye Questionnaire (DEQ-5): discrimination across self-assessed severity and aqueous tear deficient dry eye diagnoses. *Cont Lens Anterior Eye* 2010; 33:55-60
- Wolffsohn JS, Arita R, Chalmers R, Djalilian A, Dogru M, Dumbleton K, Gupta PK, Karpecki P, Lazreg S, Pult H, Sullivan BD, Tomlinson A, Tong L, Villani E, Yoon KC, Jones L, Craig JP. TFOS DEWS II Diagnostic Methodology report. *Ocul Surf* 2017; 15:539-574
- Schaumberg DA, Gulati A, Mathers WD, Clinch T, Lemp MA, Nelson JD, Foulks GN, Dana R. Development and validation of a short global dry eye symptom index. *Ocul Surf* 2007; 5:50-57
- Ngo W, Situ P, Keir N, Korb D, Blackie C, Simpson T. Psychometric properties and validation of the Standard Patient Evaluation of Eye Dryness questionnaire. *Cornea* 2013; 32:1204-1210
- Blackie CA, Solomon JD, Scaffidi RC, Greiner JV, Lemp MA, Korb DR. The relationship between dry eye symptoms and lipid layer thickness. *Cornea* 2009; 28:789-794
- Asiedu K, Kyei S, Mensah SN, Ocansey S, Abu LS, Kyere EA. Ocular Surface Disease Index (OSDI) versus the Standard Patient Evaluation of Eye Dryness (SPEED): A study of a nonclinical sample. *Cornea* 2016; 35:175-180
- The definition and classification of dry eye disease: report of the Definition and Classification Subcommittee of the International Dry Eye Workshop (2007). *Ocul Surf* 2007; 5:75-92
- Lemp MA, Bron AJ, Baudouin C, Benítez Del Castillo JM, Geffen D, Tauber J, Foulks GN, Pepose JS, Sullivan BD. Tear osmolarity in the diagnosis and management of dry eye disease. *Am J Ophthalmol* 2011; 151:792-798.e1
- Sullivan BD, Whitmer D, Nichols KK, Tomlinson A, Foulks GN, Geerling G, Pepose JS, Koshe'eff V, Porreco A, Lemp MA. An objective approach to dry eye disease severity. *Invest Ophthalmol Vis Sci* 2010; 51:6125-6130
- Potvin R, Makari S, Rapuano CJ. Tear film osmolarity and dry eye disease: a review of the literature. *Clin Ophthalmol* 2015; 9:2039-2047
- Aragona P, Aguenouz M, Rania L, Postorino E, Sommarino MS, Roszkowska AM, De Pasquale MG, Pisani A, Puzzo D. Matrix metalloproteinase 9 and transglutaminase 2 expression at the ocular surface in patients with different forms of dry eye disease. *Ophthalmology* 2015; 122:62-71

26. Sambursky R, Davitt WF 3rd, Friedberg M, Tauber S. Prospective, multi-center, clinical evaluation of point-of-care matrix metalloproteinase-9 test for confirming dry eye disease. *Cornea* 2014; 33:812–818
27. Sambursky R, Davitt WF 3rd, Latkany R, Tauber S, Starr C, Friedberg M, Dirks MS, McDonald M. Sensitivity and specificity of a point-of-care matrix metalloproteinase 9 immunoassay for diagnosing inflammation related to dry eye. *JAMA Ophthalmol* 2013; 131:24–28
28. Lanza NL, Valenzuela F, Perez VL, Galor A. The matrix metalloproteinase 9 point-of-care test in dry eye. *Ocul Surf* 2016; 14:189–195
29. Acera A, Rocha G, Vecino E, Lema I, Durán JA. Inflammatory markers in the tears of patients with ocular surface disease. *Ophthalmic Res* 2008; 40:315–321
30. Messmer EM, von Lindenfels V, Garbe A, Kampik A. Matrix metalloproteinase 9 testing in dry eye disease using a commercially available point-of-care immunoassay. *Ophthalmology* 2016; 123:2300–2308
31. Acera A, Vecino E, Duran JA. Tear MMP-9 levels as a marker of ocular surface inflammation in conjunctivochalasis. *Invest Ophthalmol Vis Sci* 2013; 54:8285–8291
32. Leonardi A, Brun P, Abatangelo G, Plebani M, Secchi AG. Tear levels and activity of matrix metalloproteinase (MMP)-1 and MMP-9 in vernal keratoconjunctivitis. *Invest Ophthalmol Vis Sci* 2003; 44:3052–3058
33. Dursun D, Kim MC, Solomon A, Pflugfelder SC. Treatment of recurrent corneal erosions with inhibitors of matrix metalloproteinase-9, doxycycline and corticosteroids. *Am J Ophthalmol* 2001; 132:8–13
34. Garrana RM, Zieske JD, Assouline M, Gipson IK. Matrix metalloproteinases in epithelia from human recurrent corneal erosion. *Invest Ophthalmol Vis Sci* 1999; 40:1266–1270. Available at: <https://ovs.arvojournals.org/article.aspx?articleid=2162202>
35. Solomon A, Dursun D, Liu Z, Xie Y, Macri A, Pflugfelder SC. Pro- and anti-inflammatory forms of interleukin-1 in the tear fluid and conjunctiva of patients with dry-eye disease. *Invest Ophthalmol Vis Sci* 2001; 42:2283–2292. Available at: <https://ovs.arvojournals.org/article.aspx?articleid=2200046>
36. Barton K, Monroy DC, Nava A, Pflugfelder SC. Inflammatory cytokines in the tears of patients with ocular rosacea. *Ophthalmology* 1997; 104:1868–1874
37. Finis D, Pischel N, Schrader S, Geerling G. Evaluation of lipid layer thickness measurement of the tear film as a diagnostic tool for Meibomian gland dysfunction. *Cornea* 2013; 32:1549–1553
38. Benito A, Pérez GM, Mirabet S, Viaseca M, Pujol J, Marr JM, Artal P. Objective optical assessment of tear-film quality dynamics in normal and mildly symptomatic dry eyes. *J Cataract Refract Surg* 2011; 37:1481–1487
39. Kassin SS, Moutsopoulos HM. Clinical manifestations and early diagnosis of Sjögren syndrome. *Arch Intern Med* 2004; 164:1275–1284
40. Peri Y, Agmon-Levin N, Theodor E, Shoenfeld Y. Sjögren's syndrome, the old and the new. *Best Pract Res Clin Rheumatol* 2012; 26:1051–117
41. Versura P, Giannaccare G, Vukatana G, Mulè R, Malavolta N, Campos EC. Predictive role of tear protein expression in the early diagnosis of Sjögren's syndrome. *Ann Clin Biochem* 2018; 55:561–570
42. Shen L, Kapsogeorgou EK, Yu M, Suresh L, Malyavantham K, Tzioufas AG, Ambrus JL Jr. Evaluation of salivary gland protein 1 antibodies in patients with primary and secondary Sjogren's syndrome. *Clin Immunol* 2014; 155:42–46
43. Shen L, Suresh L, Lindemann M, Xuan J, Kowal P, Malyavantham K, Ambrus JL Jr. Novel autoantibodies in Sjogren's syndrome. *Clin Immunol* 2012; 145:251–255
44. Horn MM, Silverman MW. Displacement technique and meibomian gland expression. *J Am Optom Assoc* 1987; 58:223–226
45. Blackie CA, Korb DR, Knop E, Bedi R, Knop N, Holland EJ. Nonobvious obstructive meibomian gland dysfunction. *Cornea* 2010; 29:1333–1345
46. Kim J. The use of vital dyes in corneal disease. *Curr Opin Ophthalmol* 2000; 11:241–247
47. Kim J, Fouks GN. Evaluation of the effect of lissamine green and rose bengal on human corneal epithelial cells. *Cornea* 1999; 18:328–332
48. Manning FJ, Wehrly SR, Fouks GN. Patient tolerance and ocular surface staining characteristics of lissamine green versus rose bengal. *Ophthalmology* 1995; 102:1953–1957
49. Craig JP, Nelson JD, Azar DT, Belmonte C, Bron AJ, Chauhan SK, de Paiva CS, Gomes JAP, Hammit KM, Jones L, Nichols JJ, Nichols KK, Novack GD, Stapleton FJ, Willcox MDP, Wolffsohn JS, Sullivan DA. TFOS DEWS II report executive summary. *Ocul Surf* 2017; 15:802–812
50. Bron AJ, Tomlinson A, Fouks GN, Pepose JS, Baudouin C, Geerling G, Nichols KK, Lemp MA. Rethinking dry eye disease: a perspective on clinical implications. *Ocul Surf* 2014; 12 (2 Suppl):S1–S31
51. Sutu C, Fukuoka H, Afshari NA. Mechanisms and management of dry eye in cataract surgery patients. *Curr Opin Ophthalmol* 2016; 27:24–30
52. Avunduk AM, Avunduk MC, Varnell ED, Kaufman HE. The comparison of efficacies of topical corticosteroids and nonsteroidal anti-inflammatory drops on dry eye patients: a clinical and immunocytochemical study. *Am J Ophthalmol* 2003; 136:593–602
53. Pflugfelder SC, Maskin SL, Anderson B, Chodosh J, Holland EJ, De Paiva CS, Bartels SP, Micuda T, Proskin HM, Vogel R. A randomized, double-masked, placebo-controlled, multicenter comparison of loteprednol etabonate ophthalmic suspension, 0.5%, and placebo for treatment of keratoconjunctivitis sicca in patients with delayed tear clearance. *Am J Ophthalmol* 2004; 138:444–457
54. Sheppard JD, Donnenfeld ED, Holland EJ, Slonim CB, Solomon R, Solomon KD, McDonald MB, Perry HD, Lane SS, Pflugfelder SC, Samudre SS. Effect of loteprednol etabonate 0.5% on initiation of dry eye treatment with topical cyclosporine 0.05%. *Eye Contact Lens* 2014; 40:289–296
55. Sall K, Stevenson OD, Mundorf TK, Reis BL. Two multicenter, randomized studies of the efficacy and safety of cyclosporine ophthalmic emulsion in moderate to severe dry eye disease. CsA Phase 3 Study Group. *Ophthalmology* 2000; 107:631–639
56. Tauber J, Karpecki P, Latkany R, Luchs J, Martel J, Sall K, Raychaudhuri A, Smith V, Semba CP. OPUS-2 Investigators. Lifitegrast ophthalmic solution 5.0% versus placebo for treatment of dry eye disease: results of the randomized phase III OPUS-2 study. *Ophthalmology* 2015; 122:2423–2431
57. Nichols KK, Holland E, Toyos MM, Peace JH, Majmudar P, Raychaudhuri A, Hamdani M, Roy M, Shojaei A. Ocular comfort assessment of lifitegrast ophthalmic solution 5.0% in OPUS-3, a phase III randomized controlled trial. *Clin Ophthalmol* 2018; 12:263–270
58. Lollett IV, Galor A. Dry eye syndrome: developments and lifitegrast in perspective. *Clin Ophthalmol* 2018; 12:125–139
59. Stevenson D, Tauber J, Reis BL. Efficacy and safety of cyclosporin A ophthalmic emulsion in the treatment of moderate-to-severe dry eye disease: a dose-ranging, randomized trial. The Cyclosporin A Phase 2 Study Group. *Ophthalmology* 2000; 107:967–974
60. Pflugfelder SC, De Paiva CS, Villarreal AL, Stern ME. Effects of sequential artificial tear and cyclosporine emulsion therapy on conjunctival goblet cell density and transforming growth factor- β 2 production. *Cornea* 2008; 27:64–69
61. Donnenfeld ED, Solomon R, Roberts CW, Wittmann JR, McDonald MB, Perry HD. Cyclosporine 0.05% to improve visual outcomes after multifocal intraocular lens implantation. *J Cataract Refract Surg* 2010; 36:1095–1100
62. Sheppard JD, Torkildsen GL, Lonsdale JD, D'Ambrosio FA Jr, McLaurin EB, Eiferman RA, Kennedy KS, Semba CP. OPUS-1 Study Group. Lifitegrast ophthalmic solution 5.0% for treatment of dry eye disease: results of the OPUS-1 phase 3 study. *Ophthalmology* 2014; 121:475–483
63. Donnenfeld ED, Perry HD, Nattis AS, Rosenberg ED. Lifitegrast for the treatment of dry eye disease in adults. *Expert Opin Pharmacother* 2017; 18:1517–1524
64. De Paiva CS, Corrales RM, Villarreal AL, Farley WJ, Li DQ, Stern ME, Pflugfelder SC. Corticosteroid and doxycycline suppress MMP-9 and inflammatory cytokine expression, MAPK activation in the corneal epithelium in experimental dry eye. *Exp Eye Res* 2006; 83:526–535
65. Calonge M. The treatment of dry eye. *Surv Ophthalmol* 2001; 45 (Suppl 2):S227–S239
66. Dogru M, Nakamura M, Shimazaki J, Tsubota K. Changing trends in the treatment of dry-eye disease. *Expert Opin Investig Drugs* 2013; 22:1581–1601
67. Shine WE, McCulley JP, Pandya AG. Minocycline effect on meibomian gland lipids in meibomianitis patients. *Exp Eye Res* 2003; 76:417–420
68. Ta CN, Shine WE, McCulley JP, Pandya A, Trattler W, Norbury JW. Effects of minocycline on the ocular flora of patients with acne rosacea or seborrheic blepharitis. *Cornea* 2003; 22:545–548
69. Aronowicz JD, Shine WE, Oral D, Vargas JM, McCulley JP. Short term oral minocycline treatment of meibomianitis. *Br J Ophthalmol* 2006; 90:856–860
70. Frucht-Pery J, Sagi E, Hemo I, Ever-Hadani P. Efficacy of doxycycline and tetracycline in ocular rosacea. *Am J Ophthalmol* 1993; 116:88–92
71. Cuevas M, González-García MJ, Castellanos E, Quispaya R, Parra Pde L, Fernández I, Calonge M. Correlations among symptoms, signs, and clinical tests in evaporative-type dry eye disease caused by Meibomian gland dysfunction (MGD). *Curr Eye Res* 2012; 37:855–863
72. Wu H, Wang Y, Dong N, Yang F, Lin Z, Shang X, Li C. Meibomian gland dysfunction determines the severity of the dry eye conditions in visual display terminal workers. *PLoS One* 2014; 9:e105575

73. Speaker MG, Milch FA, Shah MK, Eisner W, Kreiswirth BN. Role of external bacterial flora in the pathogenesis of acute postoperative endophthalmitis. *Ophthalmology* 1991; 98:639–649; discussion 650
74. Stroman DW, Mintun K, Epstein AB, Brimer CM, Patel CR, Branch JD, Najafi-Tagol K. Reduction in bacterial load using hypochlorous acid hygiene solution on ocular skin. *Clin Ophthalmol* 2017; 11:707–714
75. Gao YY, Di Pascuale MA, Elizondo A, Tseng SC. Clinical treatment of ocular demodex by lid scrub with tea tree oil. *Cornea* 2007; 26:136–143
76. Rynerson JM, Perry HD. DEBS — a unification theory for dry eye and blepharitis. *Clin Ophthalmol* 2016; 10:2455–2467
77. Lane SS, DuBiner HB, Epstein AB, Brimer CM, Patel CR, Branch JD, Holland EJ, Lemp MA, McDonald JE 2nd, Silbert DI, Blackie CA, Stevens CA, Bedi R. A new system, the LipiFlow, for the treatment of meibomian gland dysfunction. *Cornea* 2012; 31:396–404
78. Greiner JV. A single LipiFlow Thermal Pulsation System treatment improves meibomian gland function and reduces dry eye symptoms for 9 months. *Curr Eye Res* 2012; 37:272–278
79. Blackie CA, Coleman CA, Holland EJ. The sustained effect (12 months) of a single-dose vectored thermal pulsation procedure for meibomian gland dysfunction and evaporative dry eye. *Clin Ophthalmol* 2016; 10:1385–1396
80. Dell SJ. Intense pulsed light for evaporative dry eye disease. *Clin Ophthalmol* 2017; 11:1167–1173
81. Maskin SL. Intraductal meibomian gland probing relieves symptoms of obstructive meibomian gland dysfunction. *Cornea* 2010; 29:1145–1152
82. Maskin SL, Testa WR. Growth of meibomian gland tissue after intraductal meibomian gland probing in patients with obstructive meibomian gland dysfunction. *Br J Ophthalmol* 2018; 102:59–68
83. Bhargava R, Kumar P, Kumar M, Mehra N, Mishra A. A randomized controlled trial of omega-3 fatty acids in dry eye syndrome. *Int J Ophthalmol* 2013; 6:811–816
84. Kangari H, Eftekhari MH, Sardari S, Hashemi H, Salamzadeh J, Ghassemi-Broumand M, Khabazkhoob M. Short-term consumption of oral omega-3 and dry eye syndrome. *Ophthalmol* 2013; 120:2191–2196
85. Olenik A. Effectiveness and tolerability of dietary supplementation with a combination of omega-3 polyunsaturated fatty acids and antioxidants in the treatment of dry eye symptoms: results of a prospective study. *Clin Ophthalmol* 2014; 8:169–176
86. Endres S, Ghorbani R, Kelley VE, Georgilis K, Lonnemann G, van der Meer JW, Cannon JG, Rogers TS, Klempner MS, Weber PC, Schaefer EJ, Wolf SM. The effect of dietary supplementation with n-3 polyunsaturated fatty acids on the synthesis of interleukin-1 and tumor necrosis factor by mononuclear cells. *N Engl J Med* 1989; 320:265–271
87. Dry Eye Assessment and Management Study Research Group Asbell PA, Maguire MG, Pistilli M, Ying GS, Szczotka-Flynn LB, Hardten DR, Lin MC, Shtein RM. n-3 fatty acid supplementation for the treatment of dry eye disease. *N Engl J Med* 2018; 378:1681–1690
88. Cha SH, Lee JS, Oum BS, Kim CD. Corneal epithelial cellular dysfunction from benzalkonium chloride (BAC) in vitro. *Clin Experiment Ophthalmol* 2004; 32:180–184
89. Friedman NJ, Butron K, Robledo N, Loudin J, Baba SN, Chayet A. A non-randomized, open-label study to evaluate the effect of nasal stimulation on tear production in subjects with dry eye disease. *Clin Ophthalmol* 2016; 10:795–804
90. Geerling G, MacLennan S, Hartwig D. Autologous serum eye drops for ocular surface disorders. *Br J Ophthalmol* 2004; 88:1467–1474
91. Tsubota K, Goto E, Shimmura S, Shimazaki J. Treatment of persistent corneal epithelial defect by autologous serum application. *Ophthalmology* 1999; 106:1984–1989
92. Kojima T, Higuchi A, Goto E, Matsumoto Y, Dogru M, Tsubota K. Autologous serum eye drops for the treatment of dry eye diseases. *Cornea* 2008; 27 (Suppl 1):S25–S30
93. Noble BA, Loh RS, MacLennan S, Pesudovs K, Reynolds A, Bridges LR, Burr J, Stewart O, Quereshi S. Comparison of autologous serum eye drops with conventional therapy in a randomised controlled crossover trial for ocular surface disease. *Br J Ophthalmol* 2004; 88:647–652
94. Kojima T, Ishida R, Dogru M, Goto E, Matsumoto Y, Kaido M, Tsubota K. The effect of autologous serum eyedrops in the treatment of severe dry eye disease: a prospective randomized case-control study. *Am J Ophthalmol* 2005; 139:242–246
95. Kim JS, Kim JC, Na BK, Jeong JM, Song CY. Amniotic membrane patching promotes healing and inhibits proteinase activity on wound healing following acute corneal alkali burn. *Exp Eye Research* 2000; 70:329–337
96. Kolomeyer AM, Do BK, Tu Y, Chu DS. Placement of ProKera in the management of ocular manifestations of acute Stevens-Johnson syndrome in an outpatient. *Eye Contact Lens* 2013; 39:e7–e11
97. Pachigolla G, Prasher P, Di Pascuale MA, McCulley JP, McHenry JG, Mootha VV. Evaluation of the role of ProKera in the management of ocular surface and orbital disorders. *Eye Contact Lens* 2009; 35:172–175
98. Suri K, Kosker M, Raber IM, Hammersmith KM, Nagra PK, Ayres BD, Halfpenny CP, Rapuano CJ. Sutureless amniotic membrane ProKera for ocular surface disorders: short-term results. *Eye Contact Lens* 2013; 39:341–347
99. John T, Tighe S, Sheha H, Hamrah P, Salem ZM, Cheng AMS, Wang MX, Rock ND. Corneal nerve regeneration after self-retained cryopreserved amniotic membrane in dry eye disease. *J Ophthalmol* 2017; 2017:6404918
100. McDonald MB, Sheha H, Tighe S, Janik SB, Bowden FW, Chokshi AR, Singer MA, Nanda S, Qazi MA, Dierker D, Shupe AT, McMurren BJ. Treatment outcomes in the DRY Eye Amniotic Membrane (DREAM) study. *Clin Ophthalmol* 2018; 12:677–681
101. Murri MS, Moshirfar M, Birdsong OC, Ronquillo YC, Ding Y, Hoopes PC. Amniotic membrane extract and eye drops: a review of literature and clinical application. *Clin Ophthalmol* 2018; 12:1105–1112
102. Arora R, Jain S, Monga S, Narayanan R, Raina UK, Mehta DK. Efficacy of continuous wear PureVision contact lenses for therapeutic use. *Cont Lens Anterior Eye* 2004; 27:39–43
103. Bendoriceni J, Vogt U. Therapeutic use of silicone hydrogel contact lenses in children. *Eye Contact Lens* 2006; 32:104–108
104. Albiets J, Sanfilippo P, Troutbeck R, Lenton LM. Management of filamentary keratitis associated with aqueous-deficient dry eye. *Optom Vis Sci* 2003; 80:420–430
105. Tseng SC. A practical treatment algorithm for managing ocular surface and tear disorders. *Cornea* 2011; 30 (Suppl 1):S8–S14
106. Korb DR, Greiner JV, Glonek T, Esbah R, Finnemore VM, Whalen AC. Effect of periorcular humidity on the tear film lipid layer. *Cornea* 1996; 15:129–134
107. Tsubota K. The effect of wearing spectacles on the humidity of the eye. *Am J Ophthalmol* 1989; 108:92–93
108. Maron DF. Dried up. Too much screen time linked to changes in tears. *Sci Am* 2014; 311:20
109. Tsubota K, Nakamori K. Dry eyes and video display terminals. *N Engl J Med* 1993; 328:584
110. Rocha EM, Mantelli F, Nominato LF, Bonini S. Hormones and dry eye syndrome: an update on what we do and don't know. *Curr Opin Ophthalmol* 2013; 24:348–355
111. Worda C, Nepp J, Huber JC, Sator MO. Treatment of keratoconjunctivitis sicca with topical androgen. *Maturitas* 2001; 37:209–212
112. St Clair R, Lai E, Starr CE. Dry eye in the cataract surgery patient. In: Chakrabarti A, ed. *Cataract Surgery in Diseased Eyes*, 1st edition. London, England, JP Medical, 2014; 1–5; ISBN-10: 9351520927 ISBN-13: 978-9351520924
113. Walker TD. Benzalkonium toxicity. *Clin Experiment Ophthalmol* 2004; 32:657
114. Lazarus HM, Imperia PS, Botti RE, Mack RJ, Lass JH. An in vitro method which assesses corneal epithelial toxicity due to antineoplastic, preservative and antimicrobial agents. *Lens Eye Toxic Res* 1989; 6:59–85
115. Salonen E-M, Vaheeri A, Tervo T, Beuerman R. Toxicity of ingredients in artificial tears and ophthalmic drugs in a cell attachment and spreading test. *J Toxicol Cutaneous Ocul Toxicol* 1991; 10:157–166
116. Kohlhass M. Corneal sensation after cataract and refractive surgery. *J Cataract Refract Surg* 1998; 24:1399–1409
117. Donnenfeld ED, Solomon K, Perry HD, Doshi SJ, Ehrenhaus M, Solomon R, Biser S. Effect of hinge position on corneal sensation and dry eye after LASIK. *Ophthalmology* 2003; 110:1029–1030
118. Khanal S, Tomlinson A, Esakowitz L, Bhatt P, Jones D, Nabili S, Mukerji S. Changes in corneal sensitivity and tear physiology after phacoemulsification. *Ophthalmic Physiol Opt* 2008; 28:127–134
119. Oh T, Jung Y, Chang D, Kim J, Kim H. Changes in the tear film and ocular surface after cataract surgery. *Jpn J Ophthalmol* 2012; 56:113–118
120. Yu Y, Hua H, Wu M, Yu Y, Yu W, Lai K, Yao K. Evaluation of dry eye after femtosecond laser-assisted cataract surgery. *J Cataract Refract Surg* 2015; 41:2614–2623
121. Tomas-Barberan S, Fagerholm P. Influence of topical treatment on epithelial wound healing and pain in the early postoperative period

following photorefractive keratectomy. *Acta Ophthalmol Scand* 1999; 77:135-138

122. Lin JC, Repuano CJ, Laibson PR, Eagle RC Jr, Cohen EJ. Corneal melting associated with use of topical nonsteroidal anti-inflammatory drugs after ocular surgery. *Arch Ophthalmol* 2000; 118:1129-1132

OTHER CITED MATERIAL

- A. Dell S. Cataract & Refractive Lens Exchange Questionnaire. *Cataract & Refractive Surgery Today*. Available at: https://crstoday.com/wp-content/themes/crst/library/images/2017_revision_dell_questionnaire.doc. Accessed February 20, 2019
- B. Brissette AR, Bohm K, Starr CE. "The Diagnostic Utility of Normal Osmolarity in Symptomatic Patients," poster presented at the Tear Film and Ocular Surface Society Meeting, Montpellier, France, September, 2016
- C. Donnenfeld E, Holland E, Nichamin L, Wallace RB, Starr CE, Conway T, Hollander D. "A Multicenter Prospective Evaluation of the Effects of Cataract Extraction and Limbal Relaxing Incisions on Corneal Sensation and Dry Eye," poster and paper presented at the ASCRS Symposium on Cataract, IOL and Refractive Surgery, San Diego, California, USA, April, 2011

CME itemsDisclosures: Dr. Holland is a consultant to Aerie Pharmaceuticals, Azura Ophthalmics Ltd., Glaukos Corp., Kala Pharmaceuticals, Inc., Katena Products, Inc., Precision Lens, Ltd., SightLife Surgical, Inc., Sight Sciences, TearLab Corp., and Vomarix Wound Care, Inc.; conducts research for and is a consultant to and speaker for Novartis Pharmaceuticals Corp., Omeros Corp., and Senju Pharmaceutical Co.; conducts research and is a speaker for Shire; and conducts research for and is a consultant to Matipharma S.r.l., outside the submitted work.

Dr. Kim is a consultant to Actavis/Allergan, Inc., Aerie Pharmaceuticals, Alcon/Novartis, Avedro, Inc., Avellino Lab USA, Inc., Bausch & Lomb, Inc./Bausch Health Companies, Inc., BlephEx, OcuNexus Therapeutics, Inc., PowerVision, Inc., Presbyopia Therapies, LLC, Shire, Silk Technologies Ltd., and TearLab Corp.; and declares ownership in and is a consultant to Kala Pharmaceuticals, Inc., NovaBay Pharmaceuticals, Inc., Ocular Therapeutix, Inc., Omeros Corp., SightLife

Surgical, Inc., Simple Contacts, Inc., and TearScience, outside the submitted work.

Dr. Mah received a grant from Allergan, outside the submitted work.

Dr. Starr is a consultant to Alcon/Novartis, Allergan, Inc., Bausch & Lomb, Inc., BlephEx, Bruder Healthcare Co., Kala Pharmaceuticals, Inc., Rapid Pathogen Screening, Inc., Shire, Sun Pharmaceutical Industries, Ltd., and TearLab Corp., and has stock options in TearLab Corp., outside the submitted work.

Dr. Yeu is a consultant to and conducts research for Alcon Laboratories, Inc., Allergan, Inc., Bausch & Lomb, Inc., Bio-Tissue, Inc., Carl Zeiss Meditec AG, iOptics Eyewear, Kala Pharmaceuticals, Inc.; is a consultant to Aurea Medical, LLC, Avedro, Inc., Beaver-Visitec International, Bruder Healthcare, EyePoint Pharmaceuticals, Inc., Glaukos Corp., Johnson & Johnson Vision Care, Inc., LENSAR, Inc., Merck Sharp & Dohme Corp., Mynosys Cellular Devices, Inc., Novartis, Ocular Therapeutix, Inc., Ocusoft, Inc., Omeros, ScienceBased Health, Shire, Sun Pharmaceutical Industries, Ltd., TearLab Corp., TearScience, and Veracity; is a consultant to and declares ownership in Arcscan, Inc., CorneaGen, Ocular Science, and Oyster Point Pharma, Inc.; and declares ownership in Modernizing Medicine, Strathspey Crown LLC, and TopCon Medical Systems, Inc.

None of the other authors has a financial or proprietary interest in any material or method mentioned.



First author:

Christopher E. Starr, MD

Department of Ophthalmology, New York-Presbyterian Hospital, Weill Cornell Medicine of Cornell University, New York, USA